Aesthetics
MONTHLY JOURNAL FOR MEDICAL AESTHETIC PROFESSIONALS
@aestheticsgroup Aesthetics Journal Aesthetics aestheticsjournal.com

Advanced Injectables Part II

Following last month's article on mid and upper facial rejuvenation, Dr Emma Ravichandran and Dr Simon Ravichandran share their anatomical approach to lower facial rejuvenation, as presented at ACE 2015

Introduction

Facial rejuvenation procedures employing the use of dermal fillers and botulinum toxins often neglect the lower face. Simple procedures that address the nasolabial and mesolabial folds, as well as simple lip augmentation procedures, have been the prominent mainstays of treatment. Whilst this approach has some benefit in rejuvenation, it often ignores the underlying anatomical and physiological processes that can occur with ageing, resulting in artificial camouflaging. Understanding the anatomy of the area, as well as understanding the properties of the rejuvenation agents we use, will allow a more tailored approach to the individual patient, and a more natural rejuvenating outcome. In last month's article we discussed facial rejuvenation of the upper two thirds of the face, and how understanding anatomy and the rheology of products are essential when employing advanced injectable techniques. This article will continue with the same approach to describe the anatomy of the lower third of the face, and its application to facial rejuvenation procedures. In our exploration of the topic, we will describe the rejuvenation techniques and products we used during our Expert Clinic at the Aesthetics Conferences and Exhibition (ACE) 2015.

Background

Our Expert Clinic patient was a 45-year-old woman, who was medically fit and well, was not receiving any current medication and had no history of allergy. She had received toxin treatment to the upper third of her face more than a year ago, and a hyaluronic acid (HA) filler injected into her lips more than three years ago. Her expectation was to achieve a natural rejuvenation of her face with minimal downtime. Our assessment identified areas of subtle volume change in the forehead, temple, eyebrow, malar, perioral and jawline that were contributing to early signs of facial ageing.

Lips and perioral area

The perioral region may be described as the area of the face from the subnasal and the nasolabial folds to the lower border of the chin.[1] The approach to lip and perioral rejuvenation needs a thorough assessment to identify the contributions of each ageing process, and an algorithmic, stepwise approach to treatment. The goal of a lip augmentation or rejuvenation procedure is to restore a natural shape and to contour the lip.[2] Simply injecting dermal filler into the correct compartments of the lip itself is not sufficient – one must consider the surrounding perioral tissues that provides support to, and thus contributes to, the appearance of the lip. Furthermore, one must consider the ageing changes of these perioral tissues and attempt to rejuvenate these areas to preserve a harmonious, balanced appearance. The cause of the aged appearance of the lip is multifactorial. Subcutaneous volume loss in the body of the lips will cause thinning and hollowing. Tissue laxity will cause descent of the upper lip. Flattening of the philtrum columns will yield a lengthened appearance.[3] Inversion of the lips can be seen as a result of bony resorption of the maxilla and mandible, or changes in the position of the anterior teeth. Perioral rhytids will develop as a result of loss of support of the vermillion border and will be increased as a result of environmental factors such as smoking and sun damage.[4,5]

Our patient had well positioned and proportioned lips. She had a mild asymmetry of her upper lip caused by protrusion of her upper left central tooth, and had early perioral lines developing

Rejuvenation of the jawline is increasingly becoming part of routine aesthetic practice

Aesthetics
MONTHLY JOURNAL FOR MEDICAL AESTHETIC PROFESSIONALS

Understanding the anatomy of the area, as well as understanding the properties of the rejuvenation agents we use, will allow a more tailored approach to the individual patient and a more natural rejuvenating outcome

when her lips were pursed. Our management plan, based on the assessment, was to use Belotero Balance, a highly cohesive and moderately elastic filler, to increase the support of the vermillion. We prefer this product as it can be injected superficially with low risk of tyndalling effect, and its tissue integration provides a more natural feel. We have also performed this treatment with Juvéderm and Teosyal dermal fillers but find the placement needs to be slightly deeper. The filler was injected using a 25G 1.5 inch cannula with an entry point at the lateral edge of the lip made with a 23G needle. The product was placed as superficially as possible into the hypodermis. Belotero Soft was also used in this area but injected much more superficially. The intradermal placement of Belotero Soft with a 30G needle using a 'blanching technique' increases the dermal support of the vermillion, and the same technique was also used to smooth and contour some very fine lines in the upper lip. Both techniques replaced support and reduced lines without increasing the projection or volume of the lips. A further 0.2ml of Balance was deposited at the wet-dry border on the right hand side to evert and restore symmetry of the lips. This was achieved using the 25G cannula through the same entry point used for the vermillion. We find that using cannula significantly reduces the amount of post-procedural swelling and bruising a patient may expect.

Sublabial area

Reduction of lower third height and, thus, reduction in the relative proportion to the rest of the face may occur due to a decrease in the body height of the mandible, in addition to the attrition or loss of teeth. Contraction of the mentalis muscle can project the profile of the chin, and often square the lower border of the chin. It will increase the labiomental groove and add to the appearance of a shorter lower third of the face. Loss of deep fat in the sub orbicularis oris and submental areas contributes to a loss of lower third face tissue support, as evidenced by mesolabial hollows, and sublabial hollowing and prominence of a mental crease. Descent of the oral commissure may result from descent and herniation of the nasolabial fat and development of a perioral mound.[6] Activity of Depressor Anguli Oris (DAO) can further pull on the oral commissures and combine with subcutaneous fat thinning to accentuate a mesolabial hollow. Deep lines and wrinkles occur as a result of photoageing, loss of volumetric support and repeated obicularis contractions.[7]

Our patient had a well-proportioned lower third of her face. She had a strong mentalis muscle that was contributing to the development of the mental crease, projecting the chin profile and squaring the chin, resulting in a masculine appearance. Our treatment plan for this area was to soften the chin to create a more feminine lower third of the face. Eight units of Bocouture were injected into the mentalis to soften and feminise the face. Eight units of Botox would have exactly the same result. We currently use a single injection point in the midline of the mental protuberance. 0.1ml boluses of Radiesse were injected supraperiosteally with a 27G 1.5 inch needle laterally to the midline to restore the contour and support the body of the mandible. We could have achieved a similar effect with any lifting dermal filler such as Belotero Volume, Juvéderm Voluma or Emmervel Volume. 0.2ml of Belotero Intense was injected subcutaneously using a 25G 1.5 inch cannula to soften the mental crease and support the lower lip. Juvéderm 4, or Teosyal Deep Lines may also be used in this area. 2 x 2 units of Bocouture relaxed the DAO and 0.2ml of Belotero Intense was placed subcutaneously in the mesolabial area with a 25G 1.5 inch cannula to support the corners of the mouth and blend the mid and lower thirds of the face.

Jawline

Rejuvenation of the jawline is now increasingly becoming part of routine aesthetic practice. The ideal youthful appearance is of a straight line that clearly defines the face-neck junction. The two main aesthetic concerns are the development of a jowl and blunting of the jawline definition. Jowl formation is a multifactorial process

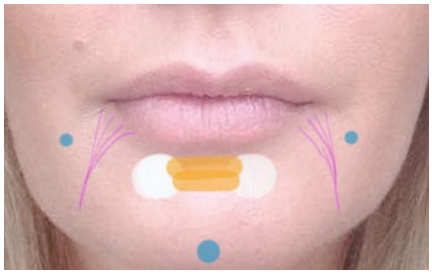

Figure 1: Blue dots indicate position of toxin injection. Purple lines show placement of Belotero Intense placed with 25G cannula in the mesolabial region. White dots show placement of supraperiosteal Radiesse. Yellow shows superficial placement of Belotero Balance in lip chin hollow area.

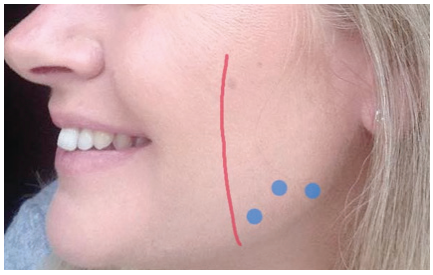

Fig 2: Blue dots represent six units of Bocouture toxin used in lower boarder of masseter for massateric debulking. Red line marks the anterior border of the masseter.

Fig 3: Red line represents the jowl area where placement of filler is avoided. White lines represent threads of Radiesse placed subcutaneously using a 25G cannula. White blocked area represents supraperiosteal bolus of Radiesse in the pre-jowl sulcus.

with contribution to the descent of tissues from the subcutaneous compartment, caused by laxity of the fibrous septae and herniation of fat compartments, superficial musculoaponeurotic layer (SMAS) and sub-SMAS laxity, and descent of the buccal fat pad.[8] Bony resorption of the pre-jowl area of the mandible accentuates the appearance.[9] The overall blunting of the jawline is caused not only by the jowl, but also has contribution from the pull of platysma, the development of submental fat, and the bony changes that effect the mandible, namely loss of height of the mandibular ramus, loss in height of the mandibular body, and increase of the mandibular angle.[9,10] Rejuvenation of the jawline, then, is a complex process that can utilise three separate approaches. We can 'push up' by augmentation of parts of the mandibular skeleton, 'pull' by revolumising the mid face and cheek to lift lax tissues, and 'relax' the downwards pull of platysma with neck toxin.

Our patient had a similar bigonial distance to the bizygomatic distance, which was giving her face a square, masculine appearance. Based on anecdotal evidence, we are of the opinion that whilst a squarer jaw is considered attractive in a Caucasian woman in the western world, the face should remain feminine in its proportions and the chin should reflect a soft pointed appearance. Masseteric debulking was carried out at ACE for our patient. This treatment is minimally invasive and slims the lower face by reducing the bigonial distance, and, in the case of our patient, feminises and rejuvenates the face by restoring an inverted triangle shape.[11] We used 3 x 6 units of Bocouture injected at each inferior masseter border. This results in a partial weakness of the masseter muscle with subsequent reduction in the bulk of the muscle fibres. We find that the best results are obtained with an initial programme of treatments every three to four months until the desired level of bulk reduction is achieved. Thereafter the treatment need only be performed infrequently. This treatment may also be used as part of a management programme for temporomandibular joint (TMJ) dysfunction or bruxism. In our experience the treatment lasts six to eight months before a repeat treatment is indicated.

Jawline sharpening

The blunting of the youthful sharp demarcation between jaw and neck can be restored to some degree using dermal fillers. Fillers can be placed in the pre-jowl sulcus, or at any position along the mandibular edge, and can be placed superficially or deep. For our patient we wanted to create a sharper definition without any volumetric widening of the jaw and we have found that this is best achieved with small volume superficial threads in the hypodermis. There was a slight amount of early jowling that was addressed with deep bolus injections in the pre-jowl sulcus. Care is taken to avoid volumisation over the jowl itself, as this is likely only to exaggerate the undesired appearance. We used a 25G cannula to place superficial threads of Radiesse in the subcutaneous layer of the jawline. Radiesse is preferred due to its high viscosity, which means significant lift is seen with small amounts of product, and because it stimulates a degree of neocollagenesis to provide a longer-lasting support to the overlying skin.[12] The anatomical structure of concern in this area is the facial artery. This is easily palpable as it crosses the lateral border of the mandible anterior to the insertion of the masseter. Vascular injury can be avoided in this area by the use of blunt tipped cannulae.[13,14] The superficial revolumisation depot injections were made directly onto the periosteum in the prejowl sulcus, an area of mandibular bony resorption that contributes to the early jowl appearance.[9] Only 0.1cc were required on each side. These boluses were placed using a 27G needle with entry perpendicular to the skin.

> The blunting of the youthful sharp demarcation between jaw and neck can be restored to some degree using dermal fillers

Discussion

Optimum results in aesthetic medicine stem from an ability to design and execute a treatment plan that exceeds the patient's expectations. A sound understanding of applied anatomy is paramount to understanding the processes by which the rejuvenation occurs. Today's practitioner needs to have a full knowledge of anatomy that he or she can link together with knowledge of products and a variety of techniques to create patient-specific, tailored treatment plans with exceptional outcomes.

Dr Emma Ravichandran qualified as a general dental practitioner in 2000, before establishing an interest for aesthetics in 2007. She co-founded Clinetix Medispa in 2010 and, alongside teaching and training commitments; she is actively involved in creating a national audit pathway for aesthetic practice.

Dr Simon Ravichandran is as an ear, nose and throat surgeon, specialising in rhinology. He trained in aesthetic medicine in 2007 and co-founded Clinetix Medispa in 2010. Dr Ravichandran has established the Scottish Advanced Aesthetic Training Programme with Glasgow University, and is the founder and chairman of the Association of Scottish Aesthetic Practitioners.

REFERENCES

1. Rohrich, Rod J Pessa, Joel E, 'The anatomy and clinical implications of perioral submuscular fat', *Plastic and reconstructive surgery*, 124(1) (2009), pp.266-71.
2. Alistair Carruthers, Jean Carruthers, Ada R. Trinidade de Almeida (2013) In: Carruthers, J and Carruthers A, *Soft Tissue Augmentation*, 3rd ed. New York: ELSEVIER. p.132-133.
3. Iblher N, Stark GB, Penna V, 'The aging perioral region - do we really know what is happening?', *Nutr Health Aging*, 16 (2012), pp.581-5.
4. Survadevara AC, 'Update on perioral cosmetic enhancement', *Current opinion in Otolaryngology and Head and Neck Surgery*, 16 (2008) pp.347-351
5. Friedman O, 'Changes associated with the aging face', *Facial Plastic Surg Clin* 12 (2005) pp.371-380.
6. Sullivan, Patrick K, Hoy, Erik A, Mehan V, Singer David P, 'An Anatomical Evaluation and Surgical Approach to the Perioral Moundin Facial Rejuvenation', *Plastic and Reconstructive Surgery,* 126(4) (2009), pp.1333-39.
7. Carruthers J, Carruthers A, 'Botulinum toxin (Botox) chemodenervation for facial rejuvenation', *Facial Plast Surg Clin* 9 (2001) pp.197–204.
8. Mendelson BC, Freeman ME, Wu W, Huggins RJ, S'urgical anatomy of the lower face: the premasseter space, the jowl, and the labiomandibular fold,' *Aesthetic Plast Surg.* 32 (2008) pp.185-95.
9. Mendelson B, Wong C, 'Changes in the Facial Skeleton With Aging: Implications and Clinical Applications in Facial Rejuvenation', *Aesth. Plast Surg,* 36 (2012), pp.753-760.
10. Roshanak Ghaffari, 'Mandibular Dimensional Changes with aging in Three Dimensional Computed Tomographic Study in 21 to 50 Year old Men and Women', *Journal of Dentomaxillary Radiology, Pathology and Surgery,* 2 (2013).
11. Jeffrey Ahn, 'Botulinum Toxin for Masseter Reduction in Asian Patients, Arch Facial Plast Surg, 6 (2004) pp.188-191.
12. Coleman K, Voigts R, Devore DP, Termin P, Coleman WP, 'Neocollagenesis after injection of calcium hydroxylapatite composition in a canine model', *Dermatologic Surgery*, 34 (2008), Suppl 1:S53-5.
13. Grunebaum LD, Bogdan Allemann I, Dayan S, Mandy S, Baumann L, 'The risk of alar necrosis associated with dermal filler injection', *Dermatol Surg,* 35 (2009) Suppl 2: pp.1635–1640.
14. Coleman SR, 'Avoidance of arterial occlusion from injection of soft tissue fillers', *Aesthet Surg J.* 22 (6) (2002), pp.555–557.